

CLINICAL PRACTICE

Arteriovenous Malformations of the Brain

Robert M. Friedlander, M.D.

This Journal feature begins with a case vignette highlighting a common clinical problem. Evidence supporting various strategies is then presented, followed by a review of formal guidelines, when they exist. The article ends with the author's clinical recommendations.

A 51-year-old woman presents with a generalized tonic–clonic seizure. After a brief postictal period, she recovers fully and does not report headache or other neurologic symptoms. She takes no medications and her medical history is unremarkable. Computed tomography of the head suggests a right occipital arteriovenous malformation, without evidence of hemorrhage. Computed tomographic angiography, magnetic resonance imaging, and magnetic resonance angiography of the brain show a right occipital arteriovenous malformation, 3.5 cm in diameter, as well as a feeding-artery aneurysm, 1.5 cm in diameter. How should her case be further evaluated and managed?

THE CLINICAL PROBLEM

From the Department of Neurosurgery, Division of Cerebrovascular Surgery, Brigham and Women's Hospital and Harvard Medical School — both in Boston. Address reprint requests to Dr. Friedlander at the Department of Neurosurgery, Brigham and Women's Hospital, 75 Francis St., Boston, MA 02115, or at rfriedlander@rics.bwh.harvard.edu.

N Engl J Med 2007;356:2704-12.
Copyright © 2007 Massachusetts Medical Society.

Arteriovenous malformations of the brain are focal abnormal conglomerations of dilated arteries and veins within brain parenchyma, in which a loss of normal vascular organization at the subarteriolar level and a lack of a capillary bed result in abnormal arteriovenous shunting (Fig. 1). Arteriovenous malformations can occur anywhere in the central nervous system; in this article, I focus on those in the brain. Small arteries involved in arteriovenous malformation are deficient in the smooth-muscle layer.¹ The tangle of abnormal arteries and veins in the malformation (often referred to as the arteriovenous malformation nidus) are connected by one fistula or, more commonly, several fistulas. The direct arteriovenous connection results in high-pressure vascular channels, particularly in veins with fibromuscular thickening and incompetent elastic lamina; these veins are at risk of rupture, often with catastrophic results.

The most common presenting sign of an arteriovenous malformation is intracerebral hemorrhage (occurring in 42 to 72% of clinically apparent arteriovenous malformations).²⁻⁷ A first hemorrhage most commonly occurs in patients between 20 and 40 years of age.²⁻⁴ Data are conflicting regarding associations between age and the risk of hemorrhage, with studies reporting either a higher risk in older patients, in younger patients, or in both (bimodal peaks) or a constant risk over time.^{4,5,8,9} Sex does not appear to affect the risk of rupture.^{6,10,11} Hemorrhage of arteriovenous malformations accounts for approximately 2% of all strokes.^{10,12} Other presenting signs of arteriovenous malformations include seizures, mass effect (from direct compression or swelling related to the malformation, putting pressure on surrounding structures), and ischemic steal (due to preferential low-resistance blood flow through the arteriovenous malformation, resulting in the hypoperfusion of adjacent structures). Even in the absence of bleeding, headaches (specifically migraines) have been associated with arteriovenous malformations.¹³

The prevalence of arteriovenous malformation is estimated at approximately 0.01% of the general population, but reported rates range from 0.001% to 0.52%.^{3,10,11,14,15} The lesions are thought to be congenital in origin. Although occa-

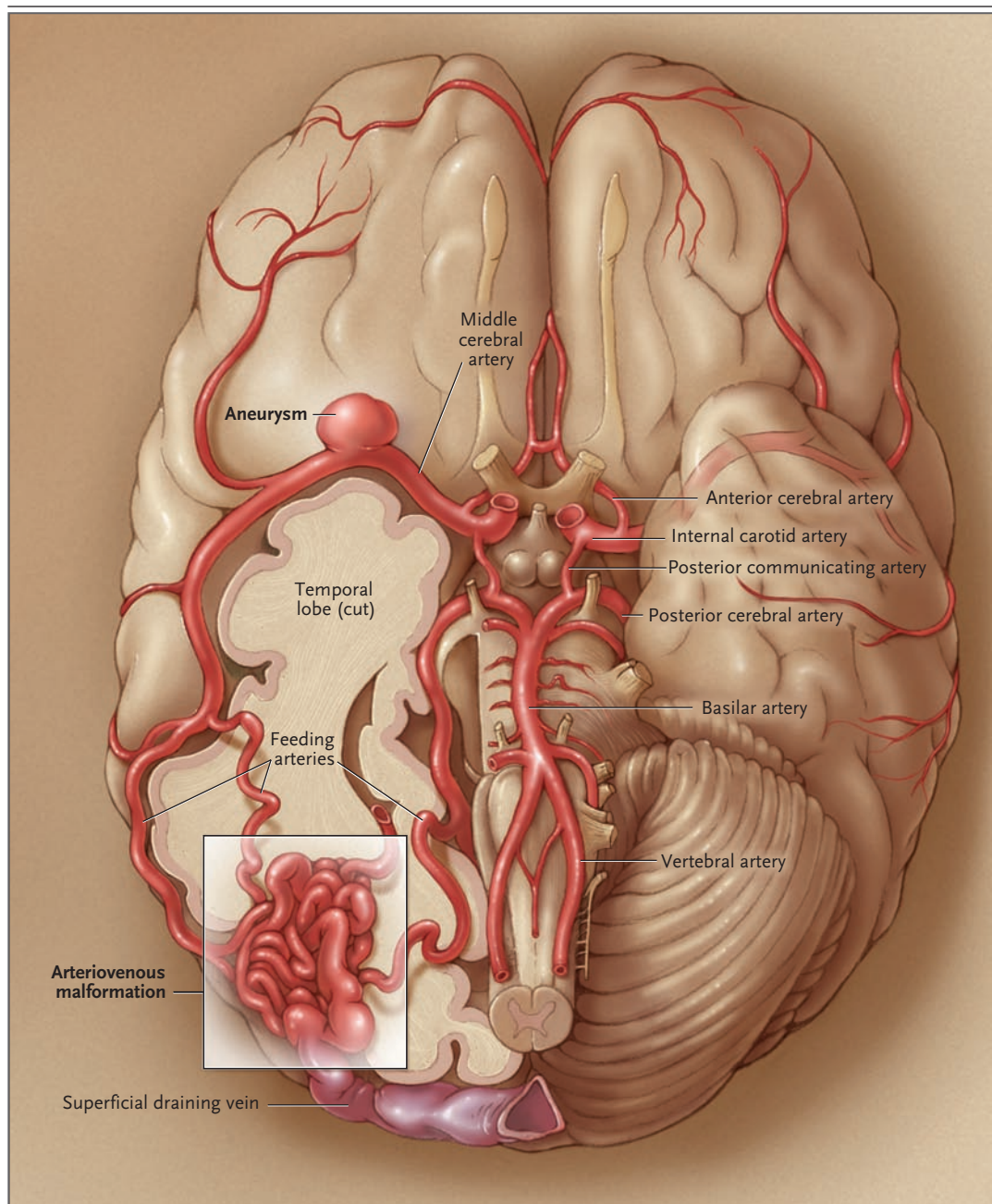


Figure 1. Arteriovenous Malformation in the Brain.

This illustration depicts the arteriovenous malformation and aneurysm in the brain of the patient in the case vignette.

sional cases are associated with other abnormalities (e.g., Osler–Weber–Rendu disease and the Sturge–Weber syndrome^{16,17}), arteriovenous malformations are not regarded as familial, and the overwhelming majority of cases are sporadic.

The increased use of advanced imaging technologies has led to the identification of more ar-

teriovenous malformations, including many that are asymptomatic.¹¹ This article focuses on the management of arteriovenous malformation, either symptomatic or incidentally discovered, in adults. The short-term management of ruptured arteriovenous malformations is beyond the scope of this article.

STRATEGIES AND EVIDENCE

EVALUATION

Imaging

Arteriovenous malformations may be visualized with the use of computed tomography (CT) or computed tomographic angiography (CTA), magnetic resonance imaging (MRI) or magnetic resonance angiography (MRA), or catheter angiography. CT scans are sensitive in the detection of acute hemorrhage, but other imaging techniques are needed to provide a detailed view of the arteriovenous malformation. CTA provides better vascular detail than MRA, whereas MRI and MRA permit better visualization of the relation of the arteriovenous malformation to surrounding cerebral structures (Fig. 2A and 2B). Additional information may be obtained with the use of functional MRI, to identify eloquent (or functional) brain tissue, and diffusion-tensor imaging, to identify important white-matter tracts. Angiography remains the standard by which to evaluate the architecture of arteriovenous malformation, including the presence or absence of associated aneurysms, presence or absence of obstruction of venous outflow, and pattern of venous drainage (Fig. 2C). Risks associated with angiography include stroke, arterial injury, and reactions with contrast medium, but the rates are less than 1%.¹⁸ Three-dimensional MRA, available in some centers, may provide additional detail to guide interventions, as may three-dimensional angiography (see the Supplementary Appendix, available with the full text of this article at www.nejm.org).

Risk Assessment

Once an arteriovenous malformation is identified, management decisions are made by weighing the risks of leaving the malformation untreated against the risks of intervention. There are currently no data from randomized, controlled trials to guide such decision making. Rather, these decisions must rely on observational data regarding outcomes with intervention and those without.

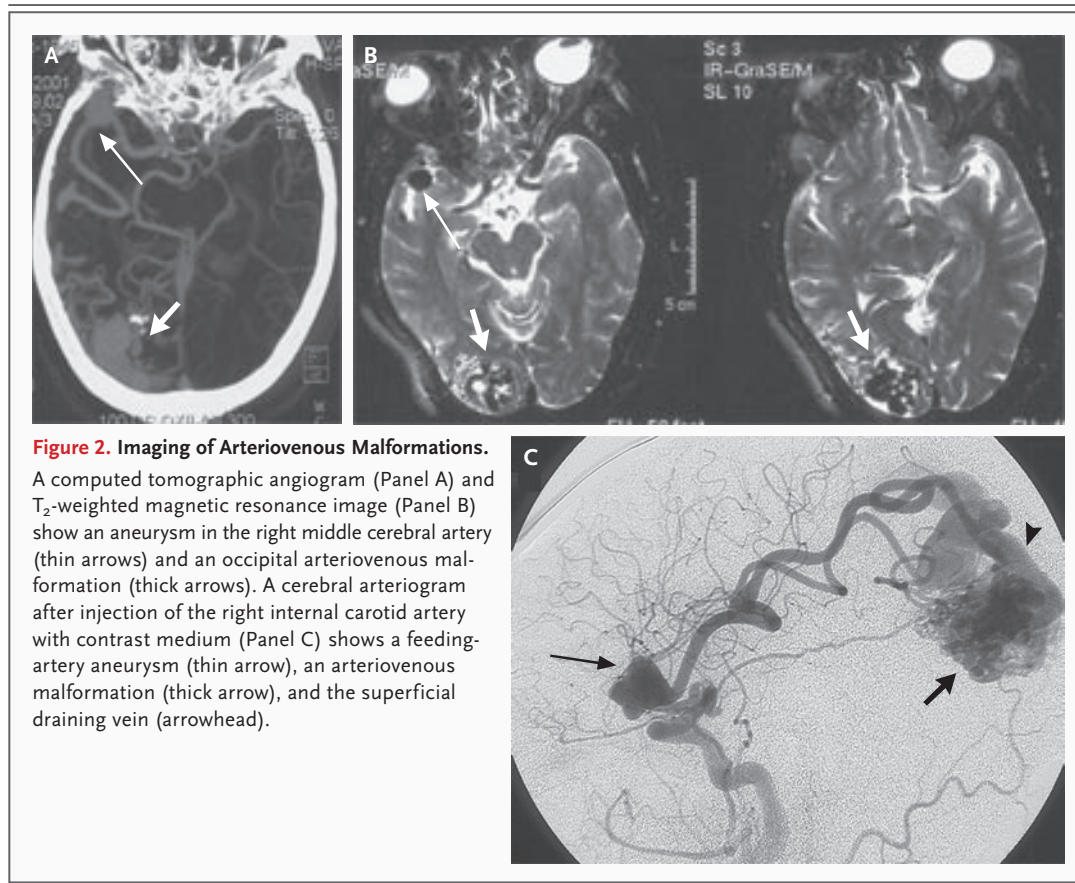
Natural History of Untreated Arteriovenous Malformations

A large autopsy study concluded that 12% of arteriovenous malformations become symptomatic during the lifetime of the patient,^{14,19} whereas other studies have suggested that most malformations will bleed at least once.^{3,5} These discrepan-

cies may relate to incomplete data on bleeding events in the autopsy studies or overestimation of the risk of bleeding in studies that are not population-based. The overall risk of hemorrhage of arteriovenous malformations is estimated at 2 to 4% per year,^{5,6,8,20} and hemorrhage is associated with a 5 to 10% chance of death and a 30 to 50% chance of permanent or disabling neurologic deficits.³

After an initial hemorrhage, the annual risk of a subsequent hemorrhage has been reported to range from 4.5 to 34.4%^{4-6,21,22}; the best estimate is approximately 6% during the first year, with a return to the baseline risk afterward.^{8,23} In a prospective study of 622 patients with arteriovenous malformations who were followed for a mean of 2.3 years, the annual risk of hemorrhage with conservative management was 5.9% among patients who presented with hemorrhage (45.3% of the group), as compared with 1.3% among those who did not.⁶ Several characteristics specific to arteriovenous malformation may also predict an increased risk of hemorrhage, including the presence of aneurysms (feeding artery, intranidal, or venous), drainage into the deep venous sinuses, deep location (i.e., basal ganglia, internal capsule, thalamus, or corpus callosum), a single draining vein, and venous stenosis; in addition, some data, but not all, suggest that risk increases with decreasing diameter of the malformation.^{6,24-27} Arterial aneurysms, which may occur in any segment of the feeding arteries, also can rupture and hemorrhage. The larger the aneurysm, the greater the risk of rupture.^{20,28}

However, the data are conflicting regarding some of these purported risk factors.^{4,6,8,27,29} For example, in the prospective, longitudinal study noted above,⁶ three features — previous hemorrhage, deep venous drainage, and deep location — were significant, independent predictors of the risk of hemorrhage of an arteriovenous malformation. The annual risk of hemorrhage of a previously unruptured arteriovenous malformation was 1% if neither of the other two factors was present, 3% if one was present, and 8% if both were present; the corresponding annual risks of hemorrhage of previously ruptured arteriovenous malformations were 5%, 11 to 15%, and 35%, respectively. However, neither the presence of aneurysms related to arteriovenous malformation (intranidal or feeding artery) nor diameter of the malformation (larger or smaller) was associated



with a significantly increased risk of hemorrhage during the follow-up period in this cohort. In the study, aneurysms related to arteriovenous malformation were associated with hemorrhage at presentation; thus, the lack of association between aneurysms and subsequent hemorrhage may reflect a selection bias (i.e., that patients presenting with bleeding aneurysms related to arteriovenous malformation were expeditiously treated and that those subsequently followed prospectively were at reduced risk for rupture).

MANAGEMENT

In cases in which the risk of hemorrhage is considered sufficiently high to warrant intervention (taking into account features of the arteriovenous malformation, age and preferences of the patient, and presentation), treatment options include surgical resection, radiosurgery, or embolization (or a combination of these, in some cases). Trials directly comparing these approaches with one another or with observation are lacking, and information on outcomes derives largely from case

series. Involvement of a multidisciplinary team with expertise in neurosurgery, endovascular intervention, and radiation therapy is recommended, to provide all therapeutic options. Complete obliteration of the arteriovenous malformation is the goal of treatment, since partial obliteration appears to offer little or no protection from hemorrhage and may actually increase the risk.

Surgical Resection

Surgical resection has the advantage of resulting in the immediate cure of the arteriovenous malformation, but there are risks associated with surgery, and even if the risk is quite low, surgery is not appropriate in all cases. Decisions as to which lesions are most amenable to surgery are commonly based on the Spetzler–Martin scale,³⁰ which is used to grade arteriovenous malformations on the basis of three characteristics shown to be predictive of surgical outcomes: the maximum diameter of the arteriovenous malformation, its location (within or outside the eloquent cortex), and the presence or absence of deep ve-

nous drainage (Table 1). The higher the grade (the sum of the scores for these three features), the more complex and risky the surgical treatment of the lesion. Depending on the age and general health of the patient and other characteristics of the arteriovenous malformation, patients with grades I to III arteriovenous malformations are typically offered surgical resection (for grade III lesions, often after embolization). In case series, reported rates of permanent weakness or paralysis, aphasia, and hemianopsia are 0 to 15%, and most report no deaths.^{31,32} In contrast, surgical resection has been associated with much greater rates of complications and death in patients with grade IV or V arteriovenous malformations; this method is thus often avoided.^{31,33,34}

Radiosurgery

Radiosurgery is often recommended if an arteriovenous malformation is less than 3 cm in diameter and is located in an eloquent area where surgery is likely to cause a neurologic deficit. Although radiosurgery avoids a craniotomy, a disadvantage is that there is a lag period of approximately 1 to 3 years from the time of treatment to potentially complete obliteration of the arteriovenous malformation, during which time there continues to be a risk of hemorrhage. Moreover, a large, prospective study of 500 patients (median follow-up, 7.8 years)³⁵ showed that the risk of hemorrhage was greatly reduced (by 88%), but not eliminated, after obliteration as compared with before radiosurgical treatment, according to imaging studies.³⁵ Reported cure rates for radiosurgery range from

81 to 90% for lesions less than 3 cm in diameter, with lower cure rates for larger lesions³⁵⁻³⁷ (in one series, 69% for lesions at least 3 cm in diameter).

Complication rates are variable and depend on the radiation dose. Early complications include seizures, nausea, vomiting, and headaches, most of which are self-limited. Delayed complications, which can occur weeks to years after treatment, include seizures, hemorrhage, radionecrosis, progressive edema, and venous congestion; in rare cases, these can be life-threatening. A recently published series reported a 5.2% incidence of transient neurologic deterioration and a 1.4% incidence of permanent neurologic deficits.³⁵ The larger the lesion, in particular those greater than 3 cm in diameter, the greater the likelihood of these complications and the lower the likelihood of the cure of the arteriovenous malformation.³⁵⁻³⁹ Recently, promising early results have been reported for larger lesions (including those of grade IV and grade V) with the use of staged radiosurgery, which targets different components of the arteriovenous malformation during different sessions.⁴⁰

Embolization

Embolization involves occluding blood flow to an arteriovenous malformation by using endovascular catheters to deposit occlusive materials into the feeding arteries and nidus. Embolization can be curative in a minority of cases, particularly for lesions less than 1 cm in diameter that are fed by a single artery.^{41,42} Improved obliteration rates (of approximately 20%) have been reported for the use of a recently developed embolic agent (Onyx),⁴² which may allow for apparently safer and more effective deployment of this glue. Complications of embolization of the arteriovenous malformation have been reported in 6 to 14% of cases; the majority of complications are minor problems related to catheterization, but major hemorrhage, major stroke, and death have also been reported.⁴²⁻⁴⁴

Management of Aneurysms Associated with Arteriovenous Malformation

Aneurysms are found in up to 58% of patients with arteriovenous malformation.⁴⁵ Management of the aneurysms varies, depending on their location and diameter. If the aneurysm is in an artery that does not feed the arteriovenous malformation, it is managed similarly to intracranial aneurysms in patients without arteriovenous malformation. Cases involving an aneurysm in an artery that feeds the arteriovenous malformation are

Table 1. Spetzler–Martin Grading Scale for Arteriovenous Malformation.*

Feature	Score
Maximum diameter	
<3 cm	1
3–6 cm	2
>6 cm	3
Location	
Noneloquent cortex tissue	0
In or adjacent to eloquent cortex tissue	1
Venous drainage	
Superficial only	0
Deep	1

* The sum of the scores is equal to the grade.

more complex. Feeding-artery aneurysms less than 5 mm in diameter have been reported to regress after treatment of the arteriovenous malformation in some cases,²⁸ but in other cases, to rupture after treatment, probably owing to the resultant increase in transmural pressure.⁴⁶ Given concern about possible rupture, microsurgical clipping or endovascular coiling of the aneurysm, particularly if greater than 7 mm in diameter,²⁴ is often performed before treatment of the arteriovenous malformation (Fig. 3). Given their location within the lesion, intranidal aneurysms are treated in conjunction with the arteriovenous malformation.

Multidisciplinary Therapy

Although data are limited, the use of more than one treatment method appears to be useful in selected patients. Embolization is often used to reduce blood flow to an arteriovenous malformation, in preparation for surgical resection (Fig. 4

and 5). Reduction of flow, particularly that contributed by deep feeding arteries, reduces the risks associated with surgery.^{7,44} Patients who have arteriovenous malformations that have hemorrhaged may also have a short-term benefit from embolization targeting the specific component of the malformation that is the likely site of hemorrhage (e.g., an associated aneurysm); surgery can then be performed when the associated swelling resolves. In some cases, such as for large arteriovenous malformations, radiosurgery has also been used as an adjunct to either partial embolization or partial resection.

AREAS OF UNCERTAINTY

Which patients with arteriovenous malformations should be treated and how best to treat them remain uncertain.^{7,33,41,47} The influence of many variables on the natural history of arterio-

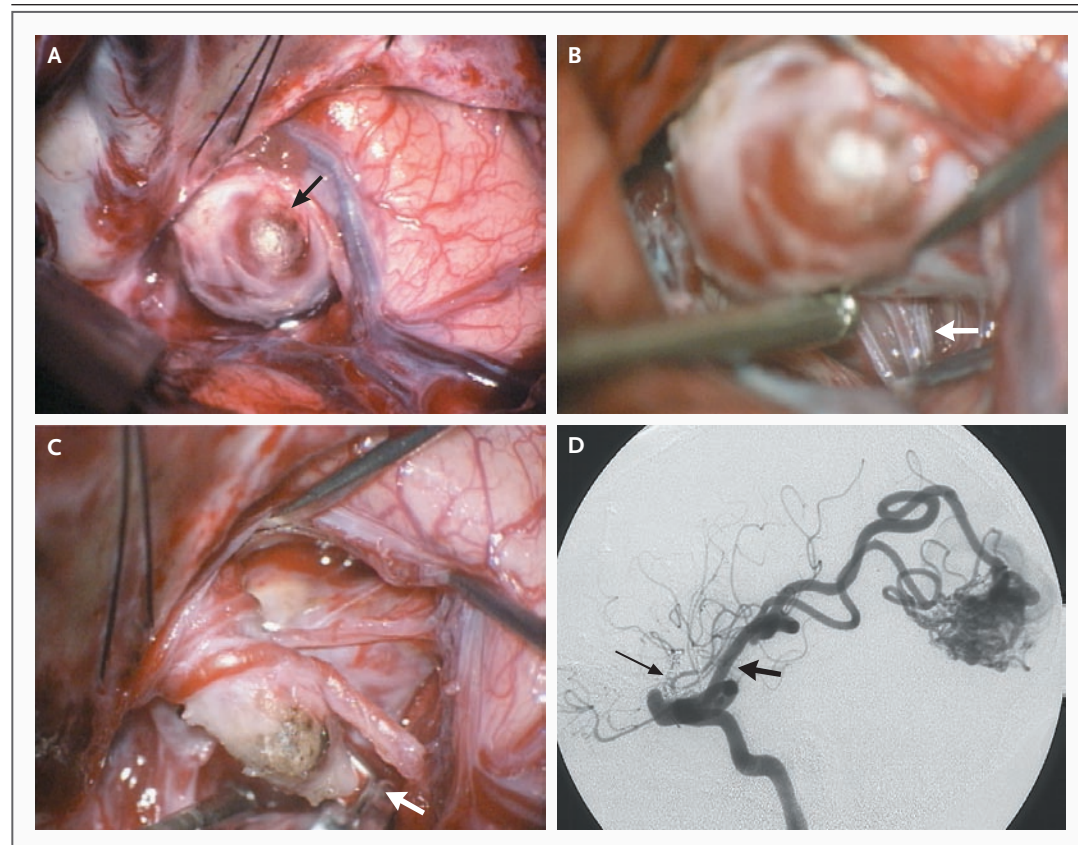


Figure 3. Microsurgical Clipping of an Aneurysm Associated with Arteriovenous Malformation.

The intraoperative micrograph shows a feeding-artery aneurysm (Panel A, arrow), normal lenticulostriate arteries (Panel B, arrow), and the clipped aneurysm (Panel C, with the arrow pointing to the clip). In Panel D, a postoperative angiogram shows obliteration of the aneurysm (thin arrow) and preservation of the middle cerebral artery (thick arrow) (see Fig. 2C for comparison).

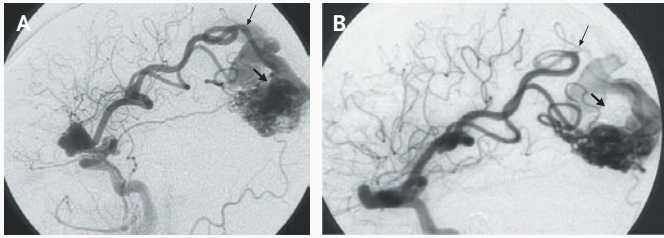


Figure 4. Embolization of the Deep Branch of the Middle Cerebral Artery.

The site of embolization (thin arrow) is shown before (Panel A) and after (Panel B) treatment, with reduction in the filling of the superior component of the arteriovenous malformation (thick arrows).

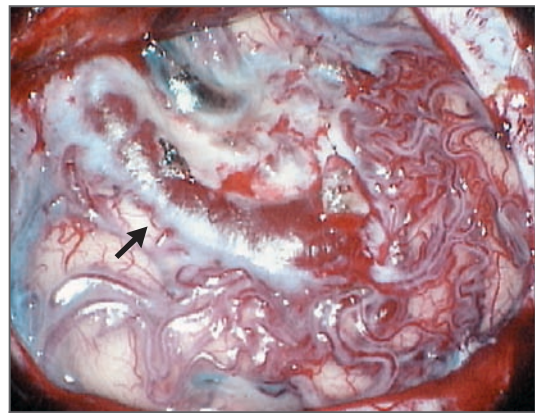


Figure 5. Intraoperative Micrograph Showing the Cortical View of the Occipital Arteriovenous Malformation.

The cortical draining vein carrying arterial blood under high pressure is shown (arrow).

venous malformations is controversial; there is particular uncertainty regarding effects of the diameter of the arteriovenous malformation, the presence or absence of associated aneurysms, and the age at presentation on the risk of hemorrhage. Furthermore, the availability of treatment methods, as well as experience with their use, varies across centers and physicians. Data from randomized trials to guide management decisions are currently lacking. An ongoing multicenter randomized trial, A Randomized Trial of Unruptured Brain Arteriovenous Malformations (ARUBA), is comparing treatment of unruptured lesions with conservative management of them. The heterogeneity of the disease process and the treatment methods used will need to be considered in applying the results of the trial, once they are available, to individual patients.

Some reports suggest that the risk of rupture of an arteriovenous malformation may be increased during pregnancy.^{48,49} Although the treatment of unruptured arteriovenous malformations is not generally recommended during pregnancy, pregnant women who present with hemorrhage of an arteriovenous malformation appear to be at high risk for rebleeding, which provides support for strong consideration of treatment during pregnancy.^{33,50}

GUIDELINES FROM PROFESSIONAL SOCIETIES

A writing group of the Stroke Council of the American Stroke Association published recommendations in 2001 for the management of arteriovenous malformations of the brain. The recommendations are based on consideration of the

known natural history of arteriovenous malformation and the published risks associated with different treatment methods.³³ Strong consideration of surgery is recommended for lesions of Spetzler–Martin grade I and grade II, and consideration of endovascular embolization followed by microsurgery is recommended for grade III lesions. Consideration of radiosurgery is recommended for lesions that may be associated with an increased rate of surgical complications, owing to their anatomical location or feeding-vessel anatomy, in particular for lesions in eloquent tissue. Because of the risks of treatment, grade IV and grade V lesions are generally not treated.

SUMMARY AND RECOMMENDATIONS

In a patient found to have an arteriovenous malformation on imaging studies, such as the one described in the case vignette, angiography is indicated to further delineate the lesion and to assess features that can be associated with an increased risk of hemorrhage. Although data from randomized trials to guide the choice of intervention are lacking, treatment (surgical resection, radiosurgery, embolization, or a combination of these) is generally considered appropriate for arteriovenous malformations that are grade I to III.^{24,33} The choice of therapy will depend on the specific features of the lesion, with consideration of the age of the patient, presence or absence of bleeding and associated aneurysms, diameter and location of associated aneurysms, and pattern of ve-

nous drainage. Given the complexity of not only the treatment but also of the decisions regarding the best course of care, patients should be cared for in centers with expertise in the various treatment methods. In the patient described in the case vignette, who has an arteriovenous malformation 3.5 cm in diameter and an associated aneurysm,

I would recommend initial microsurgical clipping of the aneurysm, followed by endovascular embolization of a main feeding artery and, thereafter, microsurgical resection of the arteriovenous malformation.

No potential conflict of interest relevant to this article was reported.

REFERENCES

- Mandybur TI, Nazek M. Cerebral arteriovenous malformations: a detailed morphological and immunohistochemical study using actin. *Arch Pathol Lab Med* 1990;114:970-3.
- Brown RD Jr, Wiebers DO, Torner JC, O'Fallon WM. Frequency of intracranial hemorrhage as a presenting symptom and subtype analysis: a population-based study of intracranial vascular malformations in Olmsted County, Minnesota. *J Neurosurg* 1996;85:29-32.
- ApSimon HT, Reef H, Phadke RV, Popovic EA. A population-based study of brain arteriovenous malformation: long-term treatment outcomes. *Stroke* 2002;33:2794-800.
- Crawford PM, West CR, Chadwick DW, Shaw MD. Arteriovenous malformations of the brain: natural history in unoperated patients. *J Neurol Neurosurg Psychiatry* 1986;49:1-10.
- Ondra SL, Troupp H, George ED, Schwab K. The natural history of symptomatic arteriovenous malformations of the brain: a 24-year follow-up assessment. *J Neurosurg* 1990;73:387-91.
- Stapf C, Mast H, Sciacca RR, et al. Predictors of hemorrhage in patients with untreated brain arteriovenous malformation. *Neurology* 2006;66:1350-5.
- Stieg PE, Batjer HH, Samson D, eds. *Intracranial arteriovenous malformations*. New York: Informa, 2007.
- Graf CJ, Perret GE, Torner JC. Bleeding from cerebral arteriovenous malformations as part of their natural history. *J Neurosurg* 1983;58:331-7.
- Stapf C, Mast H, Sciacca RR, et al. The New York Islands AVM Study: design, study progress, and initial results. *Stroke* 2003;34:e29-e33.
- Perret G, Nishioka H. Report on the cooperative study of intracranial aneurysms and subarachnoid hemorrhage. Section VI. Arteriovenous malformations: an analysis of 545 cases of cranio-cerebral arteriovenous malformations and fistulae reported to the cooperative study. *J Neurosurg* 1966;25:467-90.
- Brown RD Jr, Wiebers DO, Torner JC, O'Fallon WM. Incidence and prevalence of intracranial vascular malformations in Olmsted County, Minnesota, 1965 to 1992. *Neurology* 1996;46:949-52.
- Gross CR, Kase CS, Mohr JP, Cunningham SC, Baker WE. Stroke in south Alabama: incidence and diagnostic features — a population based study. *Stroke* 1984;15:249-55.
- Monteiro JM, Rosas MJ, Correia AP, Vaz AR. Migraine and intracranial vascular malformations. *Headache* 1993;33:563-5.
- McCormick WF. Pathology of vascular malformations of the brain. In: Wilson CB, Stein BM, eds. *Intracranial arteriovenous malformations*. Baltimore: Williams & Wilkins, 1984:44-63.
- Al-Shahi R, Fang JS, Lewis SC, Warlow CP. Prevalence of adults with brain arteriovenous malformations: a community based study in Scotland using capture-recapture analysis. *J Neurol Neurosurg Psychiatry* 2002;73:547-51.
- Kikuchi K, Kowada M, Sasajima H. Vascular malformations of the brain in hereditary hemorrhagic telangiectasia (Rendu-Osler-Weber disease). *Surg Neurol* 1994;41:374-80.
- Laufer L, Cohen A. Sturge-Weber syndrome associated with a large left hemispheric arteriovenous malformation. *Pediatr Radiol* 1994;24:272-3.
- Heiserman JE, Dean BL, Hodak JA, et al. Neurologic complications of cerebral angiography. *AJNR Am J Neuroradiol* 1994;15:1401-7.
- McCormick WF. Classification, pathology, and natural history of angiomas of the central nervous system. *Wkly Update Neurol Neurosurg* 1978;14:2-7.
- Brown RD Jr, Wiebers DO, Forbes GS. Unruptured intracranial aneurysms and arteriovenous malformations: frequency of intracranial hemorrhage and relationship of lesions. *J Neurosurg* 1990;73:859-63.
- Hartmann A, Mast H, Mohr JP, et al. Morbidity of intracranial hemorrhage in patients with cerebral arteriovenous malformation. *Stroke* 1998;29:931-4.
- Mast H, Young WL, Koennecke HC, et al. Risk of spontaneous haemorrhage after diagnosis of cerebral arteriovenous malformation. *Lancet* 1997;350:1065-8.
- Wilkins RH. Natural history of intracranial vascular malformations: a review. *Neurosurgery* 1985;16:421-30.
- Redekop G, Terbrugge K, Montanera W, Willinsky R. Arterial aneurysms associated with cerebral arteriovenous malformations: classification, incidence, and risk of hemorrhage. *J Neurosurg* 1998;89:539-46.
- Pritz MB. Ruptured supratentorial arteriovenous malformations associated with venous aneurysms. *Acta Neurochir (Wien)* 1994;128:150-62. [Erratum, *Acta Neurochir (Wien)* 1994;131:314.]
- Al-Shahi R, Warlow C. A systematic review of the frequency and prognosis of arteriovenous malformations of the brain in adults. *Brain* 2001;124:1900-26.
- Spetzler RF, Hargraves RW, McCormick PW, Zabramski JM, Flom RA, Zimmerman RS. Relationship of perfusion pressure and size to risk of hemorrhage from arteriovenous malformations. *J Neurosurg* 1992;76:918-23.
- Lasjaunias P, Piske R, Terbrugge K, Willinsky R. Cerebral arteriovenous malformations (C. AVM) and associated arterial aneurysms (AA): analysis of 101 C. AVM cases, with 37 AA in 23 patients. *Acta Neurochir (Wien)* 1988;91:29-36.
- Stefani MA, Porter PJ, terBrugge KG, Montanera W, Willinsky RA, Wallace MC. Large and deep brain arteriovenous malformations are associated with risk of future hemorrhage. *Stroke* 2002;33:1220-4.
- Spetzler RF, Martin NA. A proposed grading system for arteriovenous malformations. *J Neurosurg* 1986;65:476-83.
- Hamilton MG, Spetzler RF. The prospective application of a grading system for arteriovenous malformations. *Neurosurgery* 1994;34:2-6.
- Pikus HJ, Beach ML, Harbaugh RE. Microsurgical treatment of arteriovenous malformations: analysis and comparison with stereotactic radiosurgery. *J Neurosurg* 1998;88:641-6.
- Ogilvy CS, Stieg PE, Awad I, et al. AHA Scientific Statement: recommendations for the management of intracranial arteriovenous malformations: a statement for healthcare professionals from a special writing group of the Stroke Council, American Stroke Association. *Stroke* 2001;32:1458-71.
- Heros RC, Morcos J, Korosue K. Arteriovenous malformations of the brain: surgical management. *Clin Neurosurg* 1993;40:139-73.
- Maruyama K, Kawahara N, Shin M, et al. The risk of hemorrhage after radiosurgery for cerebral arteriovenous malformations. *N Engl J Med* 2005;352:146-53.
- Friedman WA, Bova FJ, Mendenhall WM. Linear accelerator radiosurgery for arteriovenous malformations: the relation-

- ship of size to outcome. *J Neurosurg* 1995;82:180-9.
37. Fleetwood IG, Steinberg GK. Arteriovenous malformations. *Lancet* 2002;359:863-73.
38. Flickinger JC, Kondziolka D, Maitz AH, Lunsford LD. An analysis of the dose-response for arteriovenous malformation radiosurgery and other factors affecting obliteration. *Radiother Oncol* 2002;63:347-54.
39. Barker FG II, Butler WE, Lyons S, et al. Dose-volume prediction of radiation-related complications after proton beam radiosurgery for cerebral arteriovenous malformations. *J Neurosurg* 2003;99:254-63.
40. Sirin S, Kondziolka D, Niranjan A, Flickinger JC, Maitz AH, Lunsford LD. Prospective staged volume radiosurgery for large arteriovenous malformations: indications and outcomes in otherwise untreatable patients. *Neurosurgery* 2006;58:17-27.
41. Soderman M, Andersson T, Karlsson B, Wallace MC, Edner G. Management of patients with brain arteriovenous malformations. *Eur J Radiol* 2003;46:195-205.
42. Weber W, Kis B, Siekmann R, Kuehne D. Endovascular treatment of intracranial arteriovenous malformations with onyx: technical aspects. *AJNR Am J Neuroradiol* 2007;28:371-7.
43. Hartmann A, Pile-Spellman J, Stapf C, et al. Risk of endovascular treatment of brain arteriovenous malformations. *Stroke* 2002;33:1816-20.
44. Taylor CL, Dutton K, Rappard G, et al. Complications of preoperative embolization of cerebral arteriovenous malformations. *J Neurosurg* 2004;100:810-2.
45. Turjman F, Massoud TF, Vinuela F, Sayre JW, Guglielmi G, Duckwiler G. Correlation of the angioarchitectural features of cerebral arteriovenous malformations with clinical presentation of hemorrhage. *Neurosurgery* 1995;37:856-60.
46. Batjer H, Suss RA, Samson D. Intracranial arteriovenous malformations associated with aneurysms. *Neurosurgery* 1986;18:29-35.
47. Stapf C, Mohr JP, Choi JH, Hartmann A, Mast H. Invasive treatment of unruptured brain arteriovenous malformations is experimental therapy. *Curr Opin Neurol* 2006;19:63-8.
48. Trivedi RA, Kirkpatrick PJ. Arteriovenous malformations of the cerebral circulation that rupture in pregnancy. *J Obstet Gynaecol* 2003;23:484-9.
49. Horton JC, Chambers WA, Lyons SL, Adams RD, Kjellberg RN. Pregnancy and the risk of hemorrhage from cerebral arteriovenous malformations. *Neurosurgery* 1990;27:867-71.
50. Sadasivan B, Malik GM, Lee C, Ausman JI. Vascular malformations and pregnancy. *Surg Neurol* 1990;33:305-13.

Copyright © 2007 Massachusetts Medical Society.

COLLECTIONS OF ARTICLES ON THE JOURNAL'S WEB SITE

The *Journal's* Web site (www.nejm.org) sorts published articles into more than 50 distinct clinical collections, which can be used as convenient entry points to clinical content. In each collection, articles are cited in reverse chronologic order, with the most recent first.